

VIDEOS IN CLINICAL MEDICINE

Peripheral Intravenous Cannulation

Rafael Ortega, M.D., Pavan Sekhar, M.D., Michael Song, M.D.,
Christopher J. Hansen, B.A., and Lauren Peterson

From the Department of Anesthesiology, Boston Medical Center, Boston. Address reprint requests to Dr. Ortega at the Department of Anesthesiology, Boston Medical Center, 88 E. Newton St., Boston, MA 02118, or at rortega@bu.edu.

N Engl J Med 2008;359:e26.

Copyright © 2008 Massachusetts Medical Society.

INTRODUCTION

Obtaining peripheral intravenous access is an essential skill for all physicians. Although it is considered one of the simplest invasive procedures, mastering this potentially lifesaving intervention requires refined skills and experience.

INDICATIONS

Peripheral intravenous catheterization is required in a broad range of clinical applications, including intravenous drug administration, intravenous hydration, and transfusions of blood or blood components, as well as during surgery, during emergency care, and in other situations in which direct access to the bloodstream is needed.

CONTRAINDICATIONS

Relative contraindications to insertion of a peripheral catheter at a specific site in the body may include infection, phlebitis, sclerosed veins, previous intravenous infiltration, burns or traumatic injury proximal to the insertion site, arteriovenous fistula in an extremity, and surgical procedures affecting an extremity.

Other situations may preclude obtaining peripheral intravenous access. For instance, extreme dehydration or shock may render cannulation of collapsed peripheral veins impossible. When access to peripheral veins is impossible and in situations in which accessing peripheral veins may take too long, insertion of a central venous or intraosseous catheter or peripheral venous cutdown may be required.

ANATOMY

A detailed understanding of the venous systems of the upper and lower extremities will facilitate successful cannulation. The upper extremities have two primary venous systems: the cephalic and the basilic veins (Fig. 1). The venous system of the lower extremities consists of the greater and lesser saphenous veins.

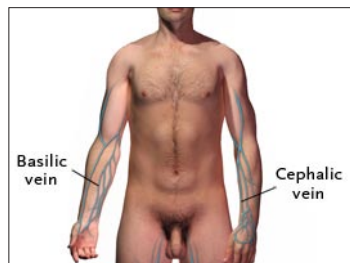


Figure 1. Basilic and Cephalic Veins of the Upper Extremities.

SITE SELECTION

The choice of a site for intravenous cannulation depends on many factors, including the intended use of the catheter, accessibility of the vein given the position of the patient, the patient's age and comfort, and the urgency of the situation. In general, upper-extremity veins are preferred, since they are more durable and are associated with fewer complications than are lower-extremity veins.

The preferred cannulation sites are the veins of the forearm. The median cubital vein, which crosses the antecubital fossa, is frequently cannulated in urgent situ-

ations, because it accommodates large-bore catheters and may be easier to cannulate than other veins in the forearm. However, caution is warranted to avoid inadvertent cannulation of the brachial artery, which usually lies just medial to the median cubital vein. The same applies for the radial and ulnar arteries at the level of the wrist — careful palpation to identify arterial pulsations should minimize the possibility of this complication.

When upper-extremity veins are inaccessible, the dorsal veins of the foot or the saphenous veins of the lower extremity may be used. Cannulation in these veins is associated with a higher incidence of thrombosis and embolism. However, this risk is lower in children and infants than in adults; therefore, the veins of the legs and feet are an acceptable alternative when cannulation of the upper extremities has failed in a child or infant. Other alternative intravenous cannulation sites include the scalp veins, used in neonates and young infants, and the external jugular vein.

EQUIPMENT

Gather the equipment and have it ready at the bedside before beginning the procedure. You will need gloves, eye protection, a nonlatex tourniquet, chlorhexidine-based antiseptic solution, sterile 2-by-2 gauze, a saline flush, a transparent occlusive dressing and tape, a catheter of an appropriate size, ranging from 14- to 24-gauge, an intravenous fluid bag with tubing, and a sharps container. A local or topical anesthetic may be required if the catheter is 20-gauge or greater.

CATHETER TYPE AND SIZE

There are many catheters, varying in style, length, and safety mechanisms (Fig. 2).

Different safety mechanisms have been developed to minimize the possibility of inadvertent needle sticks. Needles should always be discarded appropriately in a sharps container.

The size of the catheter used will depend on the clinical situation. The smallest effective catheter should be used, because small catheters allow for less resistance to blood flow around the cannula and are associated with fewer complications. Large catheters, such as 14- and 16-gauge catheters, are used in acute situations for fluid resuscitation. Other variables that may influence the size of the catheter used include age-related vessel size, the need for pressurized boluses for administration of contrast material or medication, and the viscosity of the fluid to be infused.




Figure 2. Different Types of Catheters.

PREPARATION

Explain the procedure to the patient and address any specific questions or concerns. Discuss potential complications such as bleeding, bruising, and infection. You must follow standard precautions when placing a peripheral venous catheter.

POSITIONING

When the selected site is in an upper extremity, the patient should be placed in the supine position, with the arm supported. A comfortable position for the practitioner and proper lighting are important for successful intravenous cannulation.

PROCEDURE

Tie the tourniquet with a half-knot 8 to 10 cm above the targeted insertion site. Place the tourniquet flat against the skin and bring the tourniquet ends together,

overlapping one another. Stretch the ends of the tourniquet, and with one finger, tuck the top tail beneath the bottom, directing the end away from the puncture site.

When evaluating a vein for cannulation, inspect and palpate the available veins. Gently tilt the extremity or adjust the angle of the light to reveal better the contours of the vessel. To palpate a vein, place one or two fingertips over the selected vein and gently apply pressure. Release the pressure to watch and feel the rebound of the vein on refilling.

Once you have selected the vein, clean the site with a chlorhexidine-based antiseptic solution, using a back-and-forth motion. Allow the area to dry completely. Do not repalpate the area.

If a larger-gauge catheter is used, the site may be anesthetized with a local injection, topical cream, or ethylene glycol cryoanesthesia.

To prepare the catheter, inspect the metal needle and plastic cannula for any damage or contaminants. Spin the hub of the plastic cannula to verify that it moves easily off the metal needle. Do not move the tip of the cannula over the bevel of the metal needle, since this could damage the end of the cannula.

Superficial veins are displaced easily and need to be stabilized. Use your non-dominant hand to apply traction to the skin distal to the venipuncture site. If the catheter is placed in the dorsum of the hand, grasp the patient's hand with your nondominant hand, fingers beneath the palm. Pull downward to flex the wrist and use your thumb to keep the skin taut (Fig. 3). If a forearm vein is selected, use your nondominant hand to encircle the patient's arm, place your thumb on the skin distal to the venipuncture site, and pull down. Always maintain a firm grip on the patient's hand throughout the procedure.

With your dominant hand, insert the catheter with the metal needle bevel up, at a 5- to 30-degree angle through the skin and into the vein (Fig. 4). The angle used to approach the vein is dependent on the depth of the vein. A lesser angle is required for superficial veins.

Do not insert the catheter too deeply, because of the risk of penetrating the far wall of the vein. When the catheter enters the vein lumen, watch for the initial "flashback" of blood, which will slowly fill the catheter chamber.

Once the metal needle and plastic cannula are in the lumen, lower the catheter so that it is almost parallel to the skin. Hold the end of the catheter with the thumb and index finger of your dominant hand. Maintain tension on the vein and the skin, stabilize the needle, and carefully advance the catheter into the vein.

When the catheter has entered the vein lumen completely, remove the tourniquet. To prevent blood loss from the open plastic cannula hub when the metal needle is removed, place direct pressure over the vein proximal to the end of the catheter and place a gauze pad beneath the cannula hub. Remove the metal needle from the plastic cannula and place it in the sharps container.

Never attempt to reinsert the metal needle into the plastic cannula. Doing so may shear off the plastic cannula, releasing it into the bloodstream, resulting in a possible embolus.

Make sure the tourniquet has been released, and confirm that the cannula is patent by flushing it with normal saline. The volume used depends on the size of the vein and the gauge of the catheter. Check that there is no swelling, redness, leakage, or discomfort around the insertion site.

Attach the intravenous fluid tubing to the cannula and start the fluid infusion.

Ideally, you should secure the cannula with a transparent occlusive dressing placed over the cannula hub. Confirm that the hub of the cannula is clearly visible through the dressing to facilitate monitoring.

After securing the cannula with tape, loop the intravenous tubing and secure it

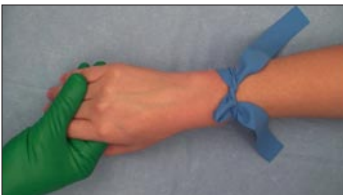

Figure 3. Keeping the Skin Taut before Insertion.

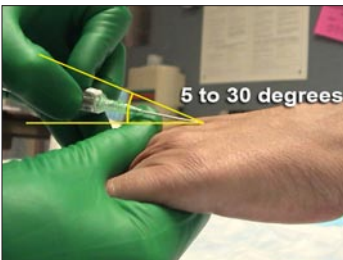


Figure 4. Inserting the Catheter.

away from the insertion site. Looping the tubing may prevent accidental displacement of the cannula, decrease the need for cannula manipulation, and lower the risk of venous contamination or irritation. It is recommended to write the date of insertion on the dressing to facilitate determining how long the cannula has been in place. To reduce the risk of infection, continue to review the indications for peripheral intravenous catheterization, and remove the cannula as soon as possible.

TROUBLESHOOTING

When a vein is difficult to see or to identify on palpation, several methods can be used to increase its dilatation. These include lowering the arm below heart level, gently tapping on the vein, instructing the patient to open and close his or her fist repeatedly, and applying a warm compress to the selected site to increase vasodilatation.¹ Transillumination or ultrasonography may also be used to help locate a vein.²

Blood might flash back into the chamber if the tip of the needle has entered the vessel lumen but the cannula itself has not yet entered the lumen. This problem can be avoided by reducing the angle of the catheter and advancing the needle a few more millimeters into the vein.

A valve within the vein may prevent advancement of an inserted catheter. If this occurs, hold the cannula hub in place, remove the tourniquet, and connect the intravenous tubing to the cannula. Running fluid into the vein may open the valve and allow the cannula to be completely inserted.

Occasionally, it is possible to advance the catheter when it is outside the vein or when the catheter has perforated the vein's opposite wall. Either situation can cause pain and swelling at the insertion site because the intravenous fluids are administered into subcutaneous tissue (Fig. 5). When this occurs, the cannula should be withdrawn completely, and another cannula placed at an alternative site.

When a cannulation attempt is unsuccessful, the subsequent attempts should be performed in a vein proximal to the initial puncture site.

COMPLICATIONS

The most common complications arising from intravenous cannulation are pain, bruising, bacterial infection, extravasation, phlebitis, thrombosis, embolism, and nerve damage.³ Proper sterile technique and selection of the appropriate catheter size may avert these complications.

Ensure proper and adequate fluid administration or flush the site with saline to prevent the more serious complications of thrombosis and embolism.

SUMMARY

The chances of successful peripheral intravenous cannulation increase with meticulous attention to proper technique, the use of proper equipment, familiarity with anatomy, and a knowledge of a variety of approaches to accessing peripheral veins.

REFERENCES

1. Benumof JL, ed. *Clinical procedures in anesthesia and intensive care*. Philadelphia: J.B. Lippincott, 1991.
2. Costantino TG, Parikh AK, Satz WA, Fojtik JP. Ultrasonography-guided peripheral intravenous access versus traditional approaches in patients with difficult intravenous access. *Ann Emerg Med* 2005; 46:456-61.
3. Tagalakis V, Kahn SR, Libman M, Blostein M. The epidemiology of peripheral vein infusion thrombophlebitis: a critical review. *Am J Med* 2002;113:146-51. Copyright © 2008 Massachusetts Medical Society.

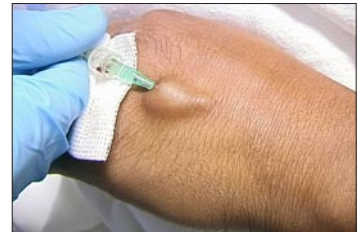

Figure 5. Swelling on Administration of Fluids into Subcutaneous Tissue.